

## Jugular Venous Pulse : An Appraisal

Naveen Garg\*, Nitish Garg\*\*

## Abstract

Physical examination of jugular venous pulse (JVP) which is an integral part of cardiovascular examination is a commonly neglected part of physical examination. Precise bedside analysis of JVP is not only possible but highly desirable. The normal JVP reflects phasic pressure changes in the right atrium and consists of three positive waves and two negative troughs. Clinicians can identify the jugular vein in a majority of patients with fair to moderate inter-observer variability. There are several studies of external and internal reference points and phlebostatic axis in human beings. The method of Lewis which states that "the CVP equals to the vertical distance between a point 5 cm below the sternal angle and the top of the neck veins", is the most accepted one. There are specific reasons for different changes in the normal jugular waveforms; sometimes characteristic wave patterns are diagnostic of few clinical conditions. Careful examination of JVP not only provides insight into cardiac haemodynamics and filling pressures but also provide electrophysiological information that can be helpful to reach a final diagnosis. Regular careful examination of JVP is essential to monitor therapy of congestive cardiac failure. Abdomino-jugular reflux and Kussmaul's sign are two additional physical signs which can be further helpful in making a final diagnosis. So we have enough reasons to believe that we can restore the art of jugular vein assessment.

*"The trouble with doctors is not that they don't know enough, but that they don't see enough."*

*- Sir Dominic J. Corrigan (1802-1880)*

Physical examination of jugular venous pulse (JVP) is an integral part of cardiovascular examination and provides valuable information to reach diagnosis and monitor therapy for many cardiac illnesses. This part of examination is often neglected by clinicians. During clinical teaching it should be emphasised that precise bedside analysis of jugular venous pulse and pressure is not only possible but also highly desirable.

Failure to identify the height of the jugular venous pulsation most commonly results from failure to look for it. Once a cardinal aspect of the clinical cardiovascular examination, jugular venous pulsations are unlikely to be sought by contemporary physicians unless we can convince them of three principles: (1) JVP is important to assess cardiac filling pressures, (2) jugular venous pressure often reflects cardiac filling pressure, (3) jugular

venous pressure can be reliably assessed at the bedside.

Although clinicians began to associate conspicuous neck veins with heart disease almost 3 centuries ago<sup>1,2</sup>, the practice of actually measuring a patient's venous pressure during physical examination is only several decades old. Even Sir James Mackenzie, who in the late 1800s described most of what we now know about bedside diagnosis of the jugular venous pulse – the a, c, and v waves, venous sounds, cannon a waves, venous waveforms in heart disease, and bedside diagnosis of atrial fibrillation (by examination only of the pulse and neck veins, before the era of electrocardiography)<sup>3,4</sup> – totally ignored the concept of measuring venous pressure.

Venous pressure became more important to clinicians in the twentieth century after direct cannulation of the antecubital vein allowed clinicians to measure pressure directly by manometry<sup>5</sup> and after Ernest Starling's investigations between 1912 and 1914 that linked venous pressure to cardiac output<sup>6-9</sup>. In his book "The Failure of Circulation," Tinsley Harrison further endorsed Starling's ideas<sup>10</sup> and, along with others, encouraged

\* Assistant Professor,

\*\* Senior Resident,

Department of Cardiology,

Sanjay Gandhi PGIMS, Lucknow (India).

clinicians to regard the elevated venous pressure as an early and essential finding of heart failure<sup>11,12</sup>. The treatment of heart failure became less empirical and more rational, and venous pressure became the objective end point that clinicians monitored frequently, often on graph paper, after administration of digitalis, phlebotomy, or diuretics<sup>13-15</sup>.

The main focus of the current review is whether and how jugular venous pulse can accurately be assessed by the clinician at the bedside and its examination as a source of anatomic, haemodynamic, and electrophysiologic information from right side of the heart.

### Central venous pressure

The central venous pressure (CVP) refers to the mean vena caval or right atrial pressure, which is equivalent to right ventricle end diastolic pressure in the absence of tricuspid stenosis. CVP is expressed in millimetres of mercury (mm Hg) or centimetres of water (cm H<sub>2</sub>O) above atmospheric pressure (this article uses cm H<sub>2</sub>O; 1.36 cm H<sub>2</sub>O = 1.0 mm Hg).

### Reference point

#### (a) Physiological reference point

The physiological reference point is the location in the cardiovascular system where the CVP is tightly regulated, changing little (if at all) during the volume shifts that occur when the patient stands or sits. To obtain reproducible measurements that are independent of position, the "zero" mark of the manometer or electronic system used to measure venous pressure should lie at the same vertical height of this point.

There are few studies of reference point (zero point) in human beings, if it even exists, although most clinicians assume that it lies in the right atrium. In investigations where the zero mark of the manometer was kept

on the plebostatic axis, (a line representing intersection of the cross-section plane through the fourth intercostal space at the sternum and the coronal plane midway between back and xiphoid; a line that traverses the posterior right atrium of most individuals) the venous pressure of healthy adults changes less than 1-2 cm H<sub>2</sub>O whether the individual is supine, prone, or in various positions between supine and upright<sup>16-18</sup>. Whether the right atrium is the actual zero point, however, is uncertain because the zero point should logically lie in the patient's midline to minimise the hydrostatic pressure changes that would occur when any individual rolls from side-to-side<sup>19</sup> most of right atrium, of course, lies in the right chest.

#### (b) The external reference point

Over the last century, investigators have proposed numerous landmarks to help clinicians to locate the level of the right atrium, most as reference point for directly measuring the supine antecubital venous pressure with a catheter (Table I). The evidence for these reference points varies, resting in some cases on anatomic dissection<sup>5,20</sup>, in others on a trial and error search for the zero point<sup>16,17</sup>, but in most, unfortunately, on no data; the landmark simply representing a convenient point<sup>14,21-26</sup>.

Sir Thomas Lewis, a pupil of Mackenzie, proposed in 1930 a simple bedside method for measuring venous pressure designed to replace the manometer, which he found too burdensome for general use. He observed that the top of the jugular veins of normal individuals (and the top of the fluid in the manometer) always came to lie within 1 to 2 cm of vertical distance from the sternal angle, whether the individual's position was supine, semiupright, or upright. If neck veins were higher than this, Lewis concluded the patient had elevated venous pressure. A

modification of this technique, commonly cited in textbooks<sup>27</sup> and review articles<sup>28</sup> and sometimes called the “method of Lewis” states that the CVP equals the vertical distance between a point 5 cm below the sternal angle and the top of the neck veins<sup>13,26,29,30</sup>, although Lewis did not make such a claim.

When the various landmarks in table I were compared with the position of a right atrial catheter on lateral chest radiographs of patients in supine position, the method of Lewis identified a point consistently 1-2 cm anterior to the catheter whereas the phlebostatic axis identified a point consistently 2-3 cm posterior<sup>31</sup>.

Table I : Proposed external reference points for measurement of venous pressure

Author	Suggested reference point*	Evidence
Von Recklinghausen <sup>21</sup> (1906)	Midway between xiphoid and back #	No data offered
Moritz <sup>5</sup> (1910)	5 cm below thoracic surface at fourth costal cartilage #	In cadavers with varying chest dimensions, a needle inserted at this point parallel to the anterior thoracic surface usually pierces the junction of vena cava and right atrium
Young <sup>22</sup> (1923)	8 cm posterior to sternum #	No data offered
Harris <sup>22</sup> (1928)	Anterior axillary line #	No data offered
Eyster <sup>24</sup> (1929)	Junction of anterior and middle thirds of anterior posterior dimension at fourth intercostal space #	No data offered
Taylor <sup>14</sup> (1930)	Midaxillary line #	No data offered
Griffith <sup>25</sup> (1934)	2½ inches below sternal angle #	No data offered
Lyons <sup>20</sup> (1938)	10 cm anterior to skin of the back \$	Usual location of right atrium in dissections of frozen cadavers, and author’s experience that reference to posterior body wall minimised variation in pressure measurements in patients with widely divergent chest dimensions
Holt <sup>16</sup> (1940)	10 cm anterior to skin of the back	Point minimising variation of venous pressure in 10 individuals with varying chest dimension who were positioned supine and then prone
Winsor <sup>17</sup> (1945)	Phlebostatic axis – (intersection of plane parallel to anterior surface midway between back and xiphoid and cross-sectional plane through fourth intercostal space at sternum)	Point minimising variation of venous pressure in 90 individuals with varying chest dimension who were placed in various positions from supine to 90 degrees upright
Borst <sup>26</sup> (1952)	5 cm below sternal angle \$	No data offered

\* Identification of reference points assumes the patient in supine.

# Reference point “accurate” only when patient in supine position.

\$ Reference point “accurate” in any position.

Obviously, the measurement of venous pressure is only as good as the reference point used.

### Bedside examination versus direct measurement of venous pressure

Clinicians can identify the jugular veins in 72-94% of patients<sup>22,33</sup> and measure the CVP with fair to moderate inter-observer agreement<sup>33</sup>. Table II presents data from the five clinical studies that compared direct measurements of CVP to clinicians' estimates from physical diagnosis.

catheterization (which tends to select unstable patients or those with confusing examinations because they have not responded to initial therapy)<sup>34,35</sup> or patients who already had an internal jugular catheter in place (which may obscure the neck veins during examination)<sup>33,36,37</sup>. Nonetheless, these studies are relevant because the patients recruited are among those with the most pressing need for accurate measurements of CVP.

Four of the five studies concluded that bedside diagnosis was inaccurate and unreliable<sup>33-36</sup>. Results were similar whether the clinicians had

Table II : Venous pressure bedside examination versus direct measurement.

Reference	External reference point		Findings
	(A) For the clinician	(B) For catheter measurement	
Clinician's estimate vs catheter measurement			
Division <sup>36</sup> (1974) (n=39)	Method of Lewis	5cm below sternal angle in supine patients	Difference in measurements# < 2cm = 57% < 3cm = 93% < 4cm = 100%
Ducas <sup>37</sup> (1983) (n=25)	Method of Lewis	5cm below sternal angle in supine patient	Difference in measurements\$ < 5.4cm = 86%
Cook <sup>33</sup> (1990) (n=50)	Not stated	Not stated	Correlation coefficient of bedside vs catheter value 0.65 to 0.74
Clinician's accuracy predicting venous pressures §			
Connors <sup>34</sup> (1983) (n=62)	Not stated	Not stated	42.7% predictions within measured range
Eisenberg <sup>35</sup> (1984) (n=103)	Not stated	Midaxillary line	55% predictions within 2.7 cm H <sub>2</sub> O of measured range

# Only data from right internal jugular shown. Results from right and left internal and external jugular veins were similar.  
 \$ Neck veins were not seen in 40% of patients positioned at 45 degrees; all these patients had measured values < 7cm or > 26cm, too low or too high to be visualized in this position.  
 § Defined as low, normal and high; < 0cm, 0 to 9.5cm and > 9.5cm (Connors et al), respectively, and < 2.7cm, 2.7-8.2cm, and > 8.2cm (Eisenberg et al), respectively.

Importantly, the patients in these studies were probably the most difficult to examine. Over 90% were in the intensive care unit, and many were on mechanical ventilators. Entry criteria included either the clinical need for right atrial

examined the external or internal jugular vein. Accuracy improved when mechanically ventilated patients were excluded<sup>33,34</sup>. In studies when clinicians were asked to assess the CVP as either low, normal, or high, they were accurate only

about half of the time, although more so if the venous pressure was predicted to be high (77-80% accuracy) than low (3-38% accuracy)<sup>28,34</sup>. Accuracy improved when mechanically ventilated patients were excluded<sup>33,34</sup>.

## Jugular venous pulse examination

Important information concerning the dynamics of the right side of the heart can be obtained by observation of the jugular venous pulse.<sup>38-41</sup> The internal jugular vein is ordinarily employed in the examination. The venous pulse can usually be analysed more readily on the right than on the left side of the neck, because the right innominate and jugular veins extend in an almost straight line cephalad to the superior vena cava (Figure 1), thus favouring transmission of the haemodynamic changes from the right atrium, while the left innominate vein is not in a straight line and may be kinked or compressed by a variety of normal structures, by a dilated aorta, or by an aneurysm.

The internal jugular vein is located deep within the neck, where it is covered by the

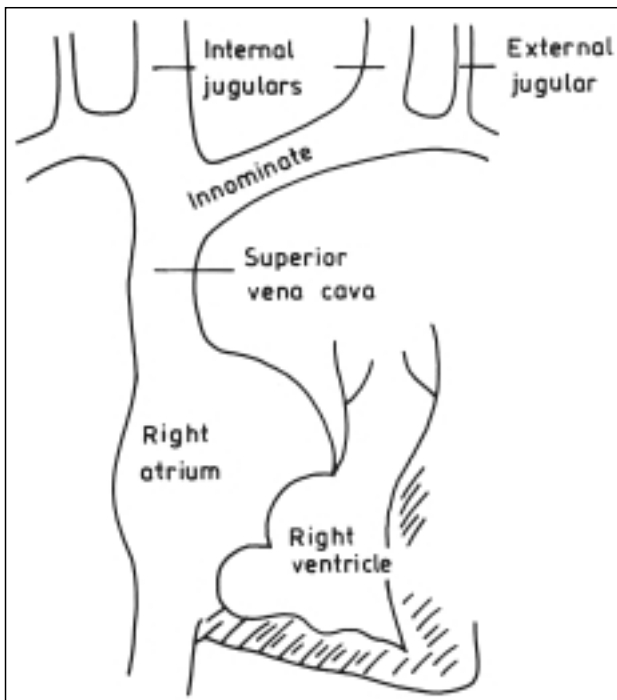


Fig. 1 : Spatial relationships of jugular veins, superior vena cava and right atrium. Note that right internal jugular vein is in more direct line with superior vena cava than external jugulars.

sternocleidomastoid muscle and is therefore not usually visible as a discrete structure, except in the presence of severe systemic venous hypertension. However, its pulsations are transmitted to the skin of the neck, where they are usually easily visible. Sometimes difficulty may be experienced in differentiating between the carotid and jugular venous pulses in the neck, particularly when the latter exhibits prominent v waves, as occurs in patients with tricuspid regurgitation in whom the valves in the internal jugular veins may be incompetent. However, there are several helpful clues<sup>42</sup>: (1) The arterial pulse is a sharply localised rapid movement that may not be readily visible but that strikes the palpating fingers with considerable force, in contrast the venous pulse, while more readily visible, often disappears when the palpating finger is placed lightly on or below the pulsation area; (2) The arterial pulse usually exhibits a single upstroke while the venous pulse has two peaks and two troughs per cardiac cycle in sinus rhythm; (3) The arterial pulsations do not change with change in the patient's position or during respiration, whereas venous pulsations usually disappear or diminish greatly in the upright position and during inspiration, unless the venous pressure is greatly elevated; (4) Compression of the root of the neck does not affect the arterial pulse but usually abolishes venous pulsation, except in the presence of extreme venous hypertension.

The patient should lie comfortably during the examination: clothing should be removed from the neck and upper thorax; although the head should rest on a pillow, it must not be elevated at a sharp angle from the trunk. The jugular venous pulse may be examined effectively by shining a light tangentially across the neck. Most patients with heart disease are examined most effectively in the 45° position, but in patients in whom venous pressure is high, a greater inclination (60° or even 90°) is required to obtain visible pulsations, while in those in whom jugular venous pressure is low, a lesser inclination (30°) is desirable. In order to amplify the pulsations of the jugular veins, it may

be helpful to place the patient in the supine position and try to increase venous return by elevating the patient's legs. Simultaneous palpation of the left carotid artery aids the examiner in relating the venous pulsations to the timing of the cardiac cycle.

Venous pressure may also be estimated by examining the veins in the dorsum of the hand. With the patient sitting or lying at a 30° elevation or greater, the arm is slowly and passively raised from dependent position. When the venous pressure is normal, the veins collapse when the dorsum of the hand reaches the level of the sternal angle of Lewis. Unfortunately, local venous obstruction or augmented peripheral venous constriction may diminish the accuracy of estimating CVP by this method. This method is especially useful in patients with markedly elevated CVP when upper level is above angle of mandible in sitting position.

Two principal observations can usually be made from examination of the neck veins, the level of venous pressure and the type of venous wave pattern. In order to estimate jugular venous pressure, the height of the oscillating top of the distended proximal portion of the internal jugular vein, which reflects right atrial pressure, should be determined. The upper limit of normal is 4 cm above the sternal angle, which corresponds to a central venous pressure of approximately 9 cm H<sub>2</sub>O, since the right atrium is approximately 5 cm below the sternal angle. When the veins in the neck collapse in a subject breathing normally in the horizontal position, it is likely that the central venous pressure is subnormal. When obstruction of veins in the lower extremities is responsible for oedema, pressure in the neck veins is not elevated and the abdomino-jugular reflux is negative.

### Normal pattern of the jugular venous pulse

Venous blood returning from the systemic capillaries is non-pulsatile; changes in volume flow created by skeletal muscles and respiratory pump are non-synchronous with the pulsatile activity of

the heart. Changes in flow and pressure caused by right atrial and ventricular filling, however, produce pulsation in the central veins that are transmitted towards the peripheral veins, opposite to the direction of blood flow. With the possible exception of the c wave, the pulsations observed in the neck are produced by right atrial and ventricular activity. Factors influencing the CVP include the total blood volume and its distribution, and right atrial contraction.

The normal JVP reflects phasic pressure changes in the right atrium and consists of three positive waves and two negative troughs (Figure 2). The events of the cardiac cycle, shown in figure 2, provide an explanation for the details of the jugular venous waveform. The a wave in the venous pulse results from venous distention due to right atrial systole, while the x descent is due to atrial relaxation and descent of the floor of the right atrium during right ventricular systole; the latter, sometimes called the x' descent, interrupts the x descent. The c wave, which occurs simultaneously with the carotid arterial pulse, is an inconstant

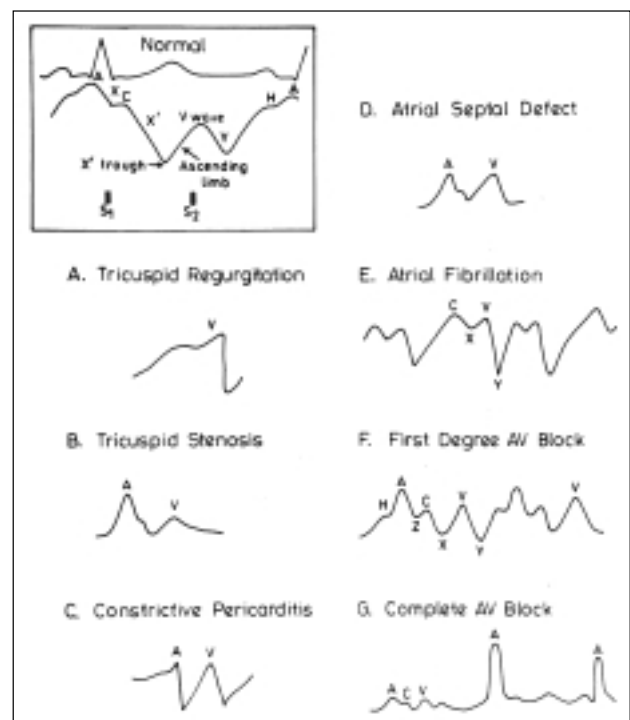


Fig. 2 : Normal and few diagnostic abnormal venous pulse wave patterns.

wave in the jugular venous pulse and/or interruption of the descent following the peak of the a wave (many investigators refer to this wave as the x' descent). The v wave results from the rise in right atrial pressure when blood flows into the right atrium during ventricular systole when the tricuspid valve is shut, and the y descent, i.e., the downslope of the v wave, is related to the decline in right atrial pressure when the tricuspid valve reopens. Following the bottom of the y descent (the y trough) and before beginning of the a wave is a period of relatively slow filling of the atrium or ventricle, the diastases period, a wave termed the h wave.

While all or most of these events can usually be recorded, they may not be readily distinguishable on inspection. The descents or downward collapsing movements of the jugular veins are more rapid, produce larger excursions, and are therefore more prominent. The x descent occurs just prior to the second heart sound, while the y descent ends after the second heart sound. The a wave occurs just before the first sound or carotid pulse and has a sharp rise and fall. The v wave occurs just after the arterial pulse and has a slower undulating pattern.

### Abnormalities of jugular venous pulse (Figure 2)

#### A. Low jugular venous pressure

1. Hypovolaemia.

#### B. Elevated jugular venous pressure

1. Intravascular volume overload conditions due to valvular disease (tricuspid or pulmonic stenosis or regurgitation), right ventricular ischaemia or infarction, cardiomyopathy or secondary to left heart failure (mitral stenosis/regurgitation, aortic stenosis/regurgitation, cardiomyopathy, myocardial ischaemia/infarction).
2. Right ventricular failure.
3. Constrictive pericarditis.
4. Pericardial effusion with tamponade physiology.

5. Obstructive atrial myxoma.
6. Superior vena caval obstruction.

#### C. Elevated "a" wave

1. Tricuspid stenosis
2. Decreased ventricular compliance due to ventricular failure, pulmonic valve stenosis, or pulmonary hypertension.

#### D. Cannon "a" wave

1. Atrial-ventricular asynchrony (atria contract against a closed tricuspid valve – as during complete heart block, premature ventricular contraction, during ventricular tachycardia, ventricular pacing and during junctional rhythm and tachycardia).

#### E. Absent "a" wave

1. Atrial fibrillation or atrial standstill.

#### F. Elevated "v" wave

1. Tricuspid regurgitation.
2. Right ventricular failure.
3. Reduced atrial compliance (restrictive cardiomyopathy).

#### G. "a" wave equal to "v" wave

1. Cardiac tamponade.
2. Constrictive pericarditis.
3. Hypervolaemia.
4. Atrial septal defect.

#### H. Prominent "x" descent

1. Cardiac tamponade.
2. Subacute constriction and possibly chronic constriction.
3. Right ventricular ischaemia with preservation of atrial contractility.
4. Atrial septal defect.

#### I. Prominent "y" descent

1. Constrictive pericarditis.
2. Restrictive cardiomyopathies.
3. Tricuspid regurgitation.
4. Atrial septal defect.

#### J. Blunted "x" descent

1. Tricuspid regurgitation.

2. Atrial fibrillation.
  3. Right atrial ischaemia.
- K. Blunted “y” descent
1. Cardiac tamponade.
  2. Right ventricular ischaemia.
  3. Tricuspid stenosis.
  4. Right atrial myxoma.

### Abdomino-jugular reflux<sup>42,43</sup>

In patients suspected of right ventricular failure but having normal resting venous pressure, the abdomino-jugular reflux (also known as hepato-jugular test) is useful.

This can be tested by applying firm pressure to the peri-umbilical region for 10-30 seconds with the patient breathing quietly while the jugular veins are observed; increased respiratory excursions or straining should be avoided. In normal subjects, jugular venous pressure either does not alter significantly or rises less than 3 cm H<sub>2</sub>O and only transiently for less than 10 sec, while abdominal pressure is continued (sensitivity 24-73%, specificity 96-100%)<sup>37,44</sup>. The dysfunctioning right ventricle, however, is unable to accept the increment in blood volume due to enhanced venous return due to abdominal compression and is transmitted to the neck veins. In patients with right ventricular failure, which often results from left sided heart failure, the venous pressure either rises rapidly or remains elevated by 4 or more centimetres until pressure is released.

### Kussmaul sign

It is the paradoxical elevation of jugular venous pressure during inspiration. Normally there is an increase in the height of waves of the JVP with a decrease in the mean jugular venous pressure during inspiration as a result of the increased filling of the right sided chamber associated with the decline in intrathoracic pressure. Although classically associated with constrictive pericarditis, it occurs only in the minority of such cases<sup>45,46</sup> and is also found in other disorders such as severe

right heart failure<sup>46,47</sup>, pulmonary embolism<sup>48</sup> and right ventricular infarction<sup>49-51</sup>.

Perhaps the fixed right ventricular distention in these patients eliminates the normal regulatory role of CVP on the Starling cardiac function curves: instead of augmenting ventricular distention and output, any increase in venous return only exaggerates the increment in CVP.

### Conclusion

In the current era of modern medicine, examination of JVP, which is an integral part of CVS examination, has become a neglected part of physical examination. It not only provides indirect assessment about cardiac haemodynamics and cardiac filling pressures, sometimes characteristic wave patterns are diagnostic and pathognomic of a few clinical conditions. So we have enough reasons to believe that we must restore the art of jugular venous pulse assessment.

### References

1. Loncisi GM. De Aneurysmatibus (1945). Wright WC (Latin translation). New York : New York Academy of Medicine, Macmillan Co.; 1952.
2. Morgagne JB. The seats and causes of diseases (1761); translated from Latin by Alexander B. (1769). New York: Classics of Medicine Library; 1983; 463-5.
3. Mackenzie J. The venous and liver pulses, and the arrhythmic contraction of the cardiac cavities. *J Pathol Bacteriol* 1894; 2: 84-154.
4. Mackenzie J. The study of the pulse: arterial, venous and hepatic and of the movements of the heart. New York : Classics of Medicine Library ; 1992.
5. Martiz F, Van tobora D. Ueber eine Methode, beim Menschen den Druck in oberflächlichen Venen exakt zu bestimmen. *Duet Arch Klin Med* 1910; 98: 475-505.
6. Knaxlton FP, Starling EH. The influence of variations in temperature and blood pressure on the performance of the isolated mammalian heart. *J Physiol* 1912; 44: 206-19.
7. Markwalder J, Starling EH. On the constancy of the systolic output under varying conditions. *J Physiol* 1914; 48: 348-56.
8. Patterson SW, Starling EH. On the mechanical factors which determine the output of the ventricles. *J Physiol* 1914; 48: 357-79.
9. Patterson SW, Piper H, Starling EH. The regulation of the

- heart beat. *J Physiol* 1914; 48: 465-513.
10. Harison TR. Failure of the circulation. Baltimore : The Williams and Wilkins Co.; 1939.
  11. Griffith GC, Chamberlain CT, Kitchell JR. Observation on the practical significance of venous pressure in health and disease with a review of the literature. *Am J Med Sci* 1934; 187: 642-9.
  12. Lewis T. Early signs of cardiac failure of the congestive type. *BMJ* 1930; 1: 849-52.
  13. Wood P. Diseases of the heart and circulation. 2nd edition, London : Eyre and Spottswode; 1956.
  14. Tylor FA, Thomas AB, Schleiter HG. A direct method for the estimation of venous blood pressure. *Proc Soc Exp Biol Med* 1930; 27: 867-71.
  15. Evans W. Venous pressure. *N Eng J Med* 1932; 207: 934-40.
  16. Holt JP. The measurement of venous pressure in man eliminating the hydrostatic factor. *Am J Physiol* 1940; 130: 635-41.
  17. Winsar T, Burch GE. Phlebostatic level, reference levels for venous pressure and measurements in man. *Proc Soc Exp Biol Med* 1945; 58: 165-9.
  18. Winsar T, Burch GE. Use of the phlebomanometer : Normal venous pressure values and a study of certain clinical aspects of venous hypertension in man. *Am Heart J* 1946; 31: 387-406.
  19. Potger KC, Elliott D. Reproducibility of central venous pressure in supine and lateral positions : A pilot evaluation of the phlebostatic axis in critically ill patients. *Heart Lung* 1994; 23: 285-99.
  20. Lyons RH, Kennedy JA, Burwell CS. The measurement of venous pressure by the direct method. *Am Heart J* 1938; 16: 657-93.
  21. Van Recklinghausen H. Unblutige Blutdruckmessung. *Arch exper Pathol Pharm* 1906; 13: 423-5.
  22. Yound FA. Direct measurement of venous pressure in man. *Cari Med Assoc J* 1923; 13: 375-504.
  23. Harris I. Venous pressure in heart disease. *Edinburgh Med J* 1928; 35: 630-50.
  24. Eyster JAE. The clinical aspects of venous pressure. New York : Macmillan; 1929.
  25. Griffith GC, Chambeain CT, Kitchell JR. A simplified apparatus for direct venous pressure determination modified from Marix and Tagora. *Am J Med Sci* 1934; 187: 371-6.
  26. Barst JGG, Molhuysen JA. Exact determination of the central venous pressure by a simple clinical method. *Lancet* 1952; 2: 304-9.
  27. Bates B, Bickley LS, Hoekelman RA. Physical examination and history taking. 6th ed. Philadelphia : J B. Lippincott; 1995.
  28. Cook DJ, Sicsel DL. Does this patient have abnormal central venous pressure? *J Am Med Assoc* 1996; 275: 630-4.
  29. Richards DW, Cournand A, Darling RC *et al*. Pressure of blood in the right auricle, in animals and in man : Under normal conditions and in right heart failure. *Am J Physiol* 1942; 136: 115-23.
  30. Bloomfield RA, Lause HD, Cournand A *et al*. Recording of right heart pressure in normal subjects and in patients with chronic pulmonary disease and various types of cardio-circulatory disease. *J Clin Invest* 1946; 25: 639-64.
  31. Devrunner F, Buehler F. "Normal central venous pressure" significance of reference point and normal range. *BMJ* 1969; 3: 148-50.
  32. Pedersen A, Hesby J. Venous pressure measurement I. Choice of zero level. *Acta Med Scand* 1951; 141: 185-94.
  33. Cook DJ. Clinical assessment of central venous pressure in the critically ill. *Am J Med Sci* 1990; 299: 175-8.
  34. Connors AF, McCaffree DR, Gray BA. Evaluation of right-heart catheterization in the critically ill patients without acute myocardial infarction. *N Eng J Med* 1983; 308: 263-7.
  35. Eisenberg PR, Jaffe AS, Schuste DP. Clinical valuation compared to pulmonary artery catheterization in the hemodynamic assessment of critically ill patients. *Crit Care Med* 1984; 12: 549-53.
  36. Davison R, Cannon R. Estimation of central venous pressure by examination of jugular veins. *Am Heart J* 1974; 87: 279-82.
  37. Ducas J, Magder S, McGregor M. Validity of the hepatojugular reflux as a clinical test for congestive heart failure. *Am J Cardiol* 1983; 52: 1299-1303.
  38. Constant J. *Beside Cardiology*, 4th ed. Boston: Little, Brown & Co; 1993.
  39. Swartz MH. Jugular venous pressure pulse: Its value in cardiac diagnosis. *Primary Cardiol* 1982; 8: 197.
  40. Stojnic BB, Brecker SJ, Xiao HB, Gibson DG. Jugular venous "a" wave in pulmonary hypertension : New insights from a Doppler echocardiographic study. *Br Heart J* 1992; 68: 187.
  41. Butman SM, Ewy GA, Standen JR. Bedside cardiovascular examination in patients with severe chronic heart failure : Importance of rest or inducible jugular venous distension. *J Am Coll Cardiol* 1993; 22: 968.
  42. Ewy GA. The abdominojugular test: Technique and haemodynamic correlates. *Ann Intern Med* 1988; 109: 456.
  43. Sochowski RA, Dubbin JD, Naqvi SZ. Clinical and hemodynamic assessment of the hepatojugular reflux. *Am J Cardiol* 1990; 66: 1002.
  44. Marantz PR, Kaplan MC, Alderman MH. Clinical diagnosis of congestive heart failure in patients with dyspnoea. *Chest* 1990; 97: 776-81.
  45. Lange RL, Botticelli JT, Tsangaris TJ *et al*. Diagnostic signs

in compressive cardiac disorders: Constrictive pericarditis, pericardial effusion, and tamponade. *Circulation* 1966; 33: 763-77.

46. Hitzig WM. On mechanisms of inspiratory filling of cervical veins and pulsus paradoxus in venous hypertension. *J Mt Sinai Hosp* 1941; 8: 625-44.
47. Wood P. Chronic constrictive pericarditis. *Am J Cardiol* 1961; 7: 48-61.
48. Burdine JA, Wallace JM. Pulsus paradoxus and Kussmaul's sign in massive pulmonary embolism. *Am J Cardiol* 1965; 15: 413-5.
49. Lorell B, Leinbach RC, Pohost GM *et al*. Right ventricular infarction : Clinical diagnosis and differentiation from cardiac tamponade and pericardial constriction. *Am J Card* 1979; 43: 465-71.
50. Cintron GB, Hernandez E, Linares E, Aranda JM. Bedside recognition, incidence and clinical course of right ventricular infarction. *Am J Cardiol* 1981; 47: 224-7.
51. Dell'Italia IJ, Starling MR, O'Rourke RA. Physical examination for exclusion of hemodynamically important right ventricular infarction. *Ann Intern Med* 1983; 99: 608-11.

**The  
Original**

# Flavedon 20

3 TABLETS DAILY

**Now  
available at a  
30% reduced Price**

## A major antianginal for all patients

- As first line treatment
- Uncontrolled on conventional drugs
- To replace a poorly tolerated antianginal
- At risk (elderly, diabetic CAD patients)

**When it comes to the heart do not compromise on quality**