

# Clinical Validity of a Negative Computed Tomography Scan in Patients With Suspected Pulmonary Embolism

## A Systematic Review

Rene Quiroz, MD, MPH

Nils Kucher, MD

Kelly H. Zou, PhD

Florian Kipfmüller, BS

Philip Costello, MD

Samuel Z. Goldhaber, MD

U. Joseph Schoepf, MD

**T**HE OPTIMAL DIAGNOSTIC IMAGING modality for acute pulmonary embolism continues to be debated. Computed tomography (CT) is readily available at most institutions and is rapidly becoming the first-line imaging test for the assessment of patients with suspected acute pulmonary embolism.<sup>1,2</sup> However, conventional single-slice spiral CT has insufficient sensitivity<sup>3-5</sup> for isolated peripheral pulmonary embolism. The clinical importance of detecting and treating peripheral pulmonary embolism remains uncertain. However, many patients with negative CT scans receive additional imaging tests to definitively rule out a diagnosis of pulmonary embolism. The additional tests increase a patient's exposure to radiation and risk of complications,<sup>6,7</sup> and increase societal health care costs.

The most reliable method to determine the accuracy of a diagnostic test to rule out a disease is to perform a prospective study in which a diagnostic criterion with a high negative predictive value (NPV) is used. Although pulmo-

**Context** The clinical validity of using computed tomography (CT) to diagnose peripheral pulmonary embolism is uncertain. Insufficient sensitivity for peripheral pulmonary embolism is considered the principal limitation of CT.

**Objective** To review studies that used a CT-based approach to rule out a diagnosis of pulmonary embolism.

**Data Sources** The medical literature databases of PubMed, MEDLINE, EMBASE, CRISP, metaRegister of Controlled Trials, and Cochrane were searched for articles published in the English language from January 1990 to May 2004.

**Study Selection** We included studies that used contrast-enhanced chest CT to rule out the diagnosis of acute pulmonary embolism, had a minimum follow-up of 3 months, and had study populations of more than 30 patients.

**Data Extraction** Two reviewers independently abstracted patient demographics, frequency of venous thromboembolic events (VTEs), CT modality (single-slice CT, multidetector-row CT, or electron-beam CT), false-negative results, and deaths attributable to pulmonary embolism. To calculate the overall negative likelihood ratio (NLR) of a VTE after a negative or inconclusive chest CT scan for pulmonary embolism, we included VTEs that were objectively confirmed by an additional imaging test despite a negative or inconclusive CT scan and objectively confirmed VTEs that occurred during clinical follow-up of at least 3 months.

**Data Synthesis** Fifteen studies met the inclusion criteria and contained a total of 3500 patients who were evaluated from October 1994 through April 2002. The overall NLR of a VTE after a negative chest CT scan for pulmonary embolism was 0.07 (95% confidence interval [CI], 0.05-0.11); and the negative predictive value (NPV) was 99.1% (95% CI, 98.7%-99.5%). The NLR of a VTE after a negative single-slice spiral CT scan for pulmonary embolism was 0.08 (95% CI, 0.05-0.13); and after a negative multidetector-row CT scan, 0.15 (95% CI, 0.05-0.43). There was no difference in risk of VTEs based on CT modality used (relative risk, 1.66; 95% CI, 0.47-5.94;  $P=.50$ ). The overall NLR of mortality attributable to pulmonary embolism was 0.01 (95% CI, 0.01-0.02) and the overall NPV was 99.4% (95% CI, 98.7%-99.9%).

**Conclusion** The clinical validity of using a CT scan to rule out pulmonary embolism is similar to that reported for conventional pulmonary angiography.

JAMA. 2005;293:2012-2017

www.jama.com

**Author Affiliations:** Department of Radiology (Drs Quiroz, Zou, Costello, and Schoepf and Mr Kipfmüller) and Cardiovascular Division, Department of Medicine (Drs Quiroz, Kucher, and Goldhaber), Brigham and Women's Hospital, Boston, Mass; Department of Health Care Policy, Harvard Medical School, Boston, Mass (Dr Zou); and

Department of Radiology, Medical University of South Carolina, Charleston (Drs Costello and Schoepf).

**Corresponding Author:** U. Joseph Schoepf, MD, Department of Radiology, Medical University of South Carolina, 169 Ashley Ave, Charleston, SC 29425 (schoepf@musc.edu).

nary angiography is considered the standard of reference to diagnose or exclude pulmonary embolism, it has limited interobserver agreement for subsegmental pulmonary embolism<sup>8</sup> with ranges of 45% to 66% reported.<sup>8,9</sup>

Thus, a validation study of chest CT compared with pulmonary angiography will not necessarily determine the true diagnostic accuracy. A practical approach to establish the validity of CT for ruling out clinically significant pulmonary embolism is to investigate the rate of a subsequent venous thromboembolic event (VTE) after anticoagulant therapy was withheld after a negative chest CT scan. We performed a systematic review of studies using a CT-based approach to rule out suspected pulmonary embolism.

## METHODS

### Literature Review

We searched the databases of PubMed, MEDLINE, EMBASE, CRISP, meta-Register of Controlled Trials, and Cochrane for articles published in the English language from January 1990 to May 2004 using the Medical Subject Heading terms *negative predictive value*, *pulmonary embolism*, *deep vein thrombosis*, *venous thromboembolism*, *computed tomography*, *chest CT*, and *spiral CT*. We also hand-searched relevant journals, corresponded with investigators and relevant experts in the field, and used the Science Citation Index to cross-reference any articles that met our selection criteria. The inclusion criteria were defined as (1) appropriate clinical follow-up (ie, office visits, telephone interviews, or questionnaires), (2) minimum follow-up of 3 months, (3) study population of more than 30 patients, and (4) chest CT performed on all patients. Studies were graded and given a quality score based on the following criteria: (1) published in peer-reviewed journal, (2) prospective design, (3) imaging technique explicitly described, (4) inclusion and exclusion criteria accurately described, (5) patient demographics collected, (6) follow-up included, and (7) recurrences and mortality reported.

Studies were excluded if (1) D-dimer testing was used as an initial triage tool and included in the study design, (2) follow-up or reporting of VTEs was inappropriate or absent, (3) the quality score was less than 5, or (4) the article was a review or editorial.

### Data Abstraction

Two reviewers (R.Q., F.K.) independently abstracted data and a third party (U.J.S.) arbitrated discrepancies between investigators. *Venous thromboembolism* was defined as either symptomatic or asymptomatic pulmonary embolism or deep vein thrombosis. We also abstracted losses to follow-up, non-diagnostic scans, CT modality (single-slice CT, multidetector-row CT, or electron-beam CT), and death attributable to a VTE.

### Study Selection

Overall, the literature search revealed 22 studies potentially suitable for inclusion.<sup>10-31</sup> Seven studies<sup>10-16</sup> were excluded because they did not meet the selection criteria or the minimum quality score, which left 15 studies<sup>17-31</sup> that were available for analyses (TABLE 1). Three studies had a quality score of 5, five studies had a quality score of 6, and 7 studies had a quality score of 7. There were 4 studies assessing recurrent VTEs in which a negative CT scan was preceded by a negative ultrasound of the lower extremities,<sup>31</sup> a ventilation perfusion scan,<sup>23,27</sup> or both<sup>18</sup> (Table 1).

### Statistical Analysis

We identified the reported number of cases of pulmonary embolism and deep vein thrombosis for each study at months 3, 6, and 12. To calculate the overall negative likelihood ratio (NLR) of a VTE after a negative or inconclusive chest CT scan for pulmonary embolism, we included VTEs that were objectively confirmed by an additional imaging test despite a negative or inconclusive CT scan and objectively confirmed VTEs that occurred during clinical follow-up. Patients who received anticoagulant therapy for reasons other than a VTE during follow-up were ex-

cluded from the analysis. We used prevalence of pulmonary embolism from each of the studies as an estimate of prior probability. The posttest probability of a VTE was defined as the product of prior odds and NLR. We used the *Q* statistic to assess heterogeneity among studies. Publication bias was examined by constructing funnel plots based on the methods of Egger et al<sup>32</sup> and Begg and Berlin.<sup>33</sup> We constructed fixed- and random-effects (DerSimonian-Laird) models<sup>34</sup> to obtain a summary estimate and 95% confidence interval (CI) for VTE and deaths related to pulmonary embolism.

Because the *Q* statistic has limited power and may fail to detect heterogeneity,<sup>35,36</sup> we also used meta-regression<sup>37</sup> to analyze the impact of additional imaging tests and CT modality (single-slice CT or multidetector-row CT) on VTEs. Therefore, we assessed the difference in VTEs between studies that used additional imaging tests prior to chest CT and studies that used chest CT only by calculating the relative risk (RR) with 95% CIs. Meta-regression was also used to investigate differences in VTEs between studies that used multidetector-row CT and those that used single-slice CT. We also used meta-regression to evaluate differences in VTEs between studies that performed 3 months of follow-up and those that extended follow-up beyond 3 months. We performed influence analysis<sup>37,38</sup> to evaluate the weight of individual studies on the summary effect estimate by omitting 1 study at a time and recalculating the summary statistic for the NLR of the remaining studies. *P* < .05 was considered statistically significant. All analyses were performed using STATA software version 8.0 (STATA Corp, College Station, Tex).

## RESULTS

Overall, 3500 patients were evaluated from October 1994 through April 2002 in 15 studies originating from Austria, Canada, France, Ireland, the Netherlands, Sweden, and the United States. Three CT modalities were used in the

**Table 1.** Study Characteristics and Reported Thromboembolic Events

Source	Total Follow-up, mo	No. of Cases With Thromboembolic Event at End of Follow-up		Total No. of Negative CT Scans	Diagnostic Process and Method
		Pulmonary Embolism	Deep Vein Thrombosis		
Donato et al, <sup>17</sup> 2003	3	2	2	239	Sequential medical record review of CT scans; pretest probability and alternate test results recorded
Ferretti et al, <sup>18</sup> 1997	3	3	3	112	Indeterminate ventilation perfusion scan, Doppler ultrasonography of legs, CT within 72 h of ventilation perfusion scan; angiography if CT scan was negative
Garg et al, <sup>19</sup> 1999	6	1	0	78	Medical record review of CT scans; data on alternate test results unavailable
Goodman et al, <sup>20</sup> 2000	3	2	0	198	Prospective, negative CT scan; risk factors recorded at time of scan; Doppler ultrasonogram obtained in 42% of patients
Gottsäter et al, <sup>21</sup> 2001	3	3	0	215	Medical record review for negative results; alternate imaging modalities recorded
Kavanagh et al, <sup>22</sup> 2004	4	1	0	68	Prospective, CT scan only (1 patient with ventilation perfusion scan, no ultrasound)
Krestan et al, <sup>23</sup> 2004	6	1	0	220	Negative CT scan, recorded ventilation perfusion scan, pulmonary angiogram, venogram, and ultrasound
Lombard et al, <sup>24</sup> 2003	3	2	0	51	Medical record review of radiology records; recorded ventilation perfusion scan prior to CT
Lomis et al, <sup>25</sup> 1999	6	0	0	100	Prospective CT scans; ultrasound, pulmonary angiogram, and ventilation perfusion recorded
Nilsson et al, <sup>26</sup> 2002	3	4	0	441	Medical record review of referrals to thoracic radiology; auxiliary ventilation perfusion information recorded
Ost et al, <sup>27</sup> 2001	6	2	1	71	Prospective, clinical suspicion and nondiagnostic ventilation perfusion scan; various laboratory tests recorded; ultrasound results mentioned
Remy-Jardin et al, <sup>28</sup> 2002	3	1	0	153	Referrals to specialty department; additional tests could be ordered and were recorded (ventilation perfusion, ultrasound, pulmonary angiography)
Swensen et al, <sup>29</sup> 2002	3	8	0	993	Additional studies recorded, retrospective retrieval of CT findings
Tillie-Leblond et al, <sup>30</sup> 2002	12	3	0	185	Referrals to pulmonology department, recorded additional tests
van Strijen et al, <sup>31</sup> 2003	3	3	0	376	3-Center study, follow-up recorded use of other imaging modalities

Abbreviation: CT, computed tomographic.

included studies: 12 used single-slice CT, 2 used multidetector-row CT, and 1 used electron-beam CT. Overall, there were 153 nondiagnostic scans and 199 patients were lost to follow-up (TABLE 2). Patient follow-up ranged from 3 to 12 months (Table 1). One study<sup>30</sup> failed to report VTEs in patients who underwent additional imaging tests after a negative or inconclusive chest CT scan (Table 2). For this study, we included VTEs that occurred during follow-up only.

A random-effects model was used for the 15 relevant studies ( $\chi^2_{14} = 58.6$ ;  $P < .001$  for heterogeneity). The publi-

cation bias was  $P > .20$  for both evaluation plots.

The overall NLR of a VTE after a negative chest CT scan for pulmonary embolism was 0.07 (95% CI, 0.05-0.11) and the NPV was 99.1% (95% CI, 98.7%-99.5%; FIGURE 1). The NLR of a VTE after a negative single-slice CT scan for pulmonary embolism was 0.08 (95% CI, 0.05-0.13); and after multidetector-row CT, 0.15 (95% CI, 0.05-0.43). A total of 36 pulmonary embolism events and 6 deep vein thrombosis (without pulmonary embolism) events were observed at months 3, 4, 6, or 12. There were 15 deaths attributable to a

VTE, either by autopsy (10 studies) or record review of death certificates (15 studies). The overall NPV for mortality attributable to pulmonary embolism was 99.4% (95% CI, 98.7%-99.9%) and the overall NLR was 0.01 (95% CI, 0.01-0.02).

Compared with studies that used chest CT imaging only, the RR of VTEs in studies that used additional imaging tests prior to chest CT was not significantly reduced (RR, 0.51; 95% CI, 0.22-1.17;  $P = .11$ ). Compared with studies that used multidetector-row CT, the RR of VTEs in studies that used single-slice CT was not significantly increased (RR, 1.66; 95%

**Table 2.** Patient Exclusion Criteria and False-Negative Findings

Source	Type of Scan				No. Lost to Follow-up/ Total*	No. of Patients With Exclusions/ Total*†	False-Negative Results‡	
	Initial	Negative	Nondiagnostic/ Total*	Final			Pulmonary Embolism	Deep Vein Thrombosis
Donato et al, <sup>17</sup> 2003	433	314	14/314	240	4/314	56/300	1	0
Ferretti et al, <sup>18</sup> 1997	164	125	0	116	1/125	8/125	1	4
Garg et al, <sup>19</sup> 1999	126	84	2/84	78	1/82	3/82	0	0
Goodman et al, <sup>20</sup> 2000	393	285	NA	198	24/285	63/285	0	0
Gottsäter et al, <sup>21</sup> 2001	305	244	17/244	220	3/244	21/244	0	5
Kavanagh et al, <sup>22</sup> 2004	102	85	0	79	0	6/85	0	0
Krestan et al, <sup>23</sup> 2004	485	325	26/485	230	56/325	41/325	2	8
Lombard et al, <sup>24</sup> 2003	62	51	0	41	7/51	3/51	0	0
Lomis et al, <sup>25</sup> 1999	143	121	8/121	91	13/121	9/121	0	3
Nilsson et al, <sup>26</sup> 2002	751	593	12/593	449	45/593	87/593	1	0
Ost et al, <sup>27</sup> 2001	103	81	8/81	73	0	0	1	1
Remy-Jardin et al, <sup>28</sup> 2002	259	208	20/208	173	12/208	3/208	0	10
Swensen et al, <sup>29</sup> 2002	1512	1010	NA	982	19/1010	9/1010	0	11
Tillie-Leblond et al, <sup>30</sup> 2002	334	237	38/237	185	14/237	0	NR	NR
van Strijen et al, <sup>31</sup> 2003	510	386	8/386	378	0	0	0	5

Abbreviation: NR, data not reported by Tillie-Leblond et al.<sup>30</sup>

\*The total number of patients in a particular category is provided if the total is not the same as the total in the initial scan column.

†Anticoagulation.

‡Venous thromboembolism diagnosed by additional imaging test despite a negative or inconclusive chest computed tomographic scan.

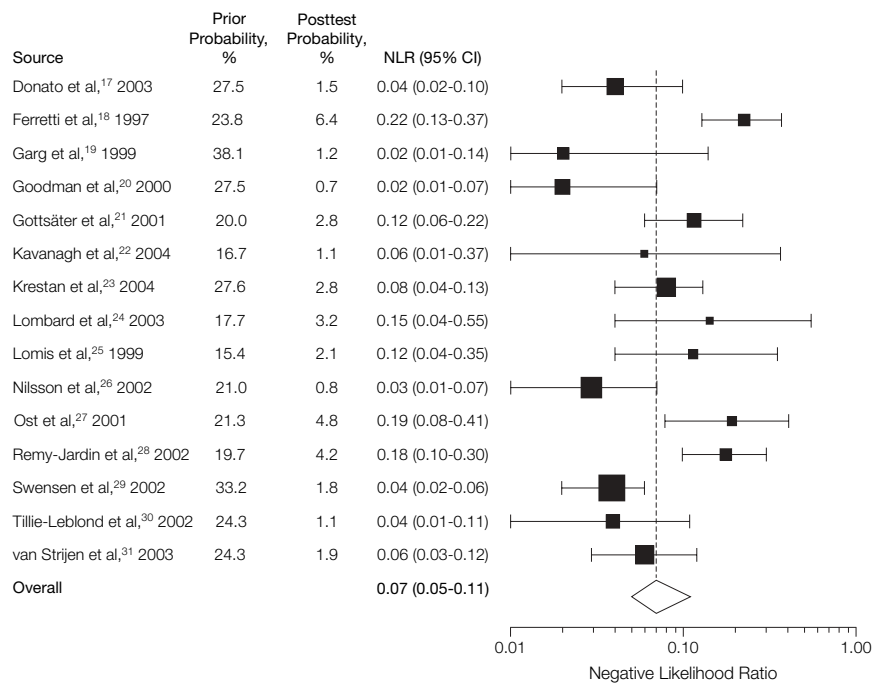
CI, 0.47-5.94;  $P = .50$ ). Compared with studies that performed 3-month follow-up, the RR of a VTE was not increased in studies that performed follow-up beyond 3 months (RR, 1.05; 95% CI, 0.43-2.52;  $P = .11$ ). There was no evidence of an individual study dominance on the summary effect estimate by influence analysis (FIGURE 2).

## COMMENT

Pooled results involving 15 studies and 3500 patients with suspected pulmonary embolism suggest that clinical outcome is not adversely affected if anticoagulant therapy is withheld based on a negative CT scan. The overall NPV of 99.1% for VTEs in our analysis compares favorably with previously reported NPVs of 98.4%<sup>39</sup> and 100%<sup>40</sup> when pulmonary angiography was used and is superior to a negative/low-probability ventilation perfusion scan (range, 75.9%-88%).<sup>14,41</sup> The improved visualization of peripheral pulmonary arteries that has been achieved by the ongoing technical refinement of CT techniques<sup>42-44</sup> should further increase the clinical validity of chest CT.

Inaccurate detection of isolated peripheral pulmonary embolism is considered the principal limitation of CT,

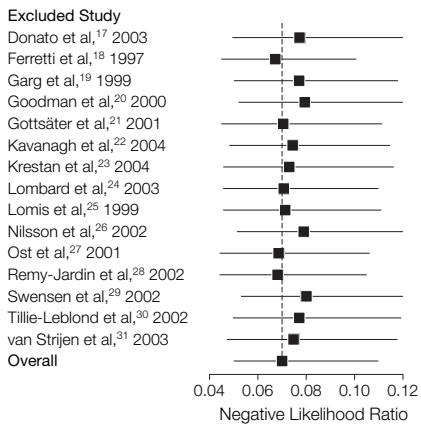
**Figure 1.** Posttest Probability of a Venous Thromboembolism Event After a Negative Chest Computed Tomographic Scan for Pulmonary Embolism



The size of each square is proportional to the precision of the estimate (number of patients, number of events, and variance). The dashed vertical line represents the overall negative likelihood ratio of 0.07.

although the clinical significance of small isolated clots in the absence of central embolism is not well under-

stood. The majority of studies that were included in our analysis used conventional single-slice CT for which rates of

**Figure 2.** Influence Analysis of Venous Thromboembolism Events

One study at a time was omitted from the meta-analysis. The y-axis denotes the omitted study and the reestimated negative likelihood ratio by excluding the data of that study from the analysis. The vertical dashed line represents the overall negative likelihood ratio of 0.07.

30% and higher were reported for missing a diagnosis of peripheral pulmonary embolism.<sup>3-5</sup> Thus, it can be assumed that a significant number of patients in our pooled analysis had peripheral pulmonary embolism, which was not diagnosed. However, the low incidence of VTEs during follow-up across all studies shows that even if peripheral emboli were missed and subsequently not treated based on a negative CT scan, the patient outcome was not adversely affected.

Chest CT to exclude pulmonary embolism is often used in combination with other imaging tests, including ventilation perfusion scan and venous ultrasound of the lower extremities, as it was done in the majority of the studies included in our meta-analysis. In addition, chest CT can be combined with CT venography of the lower extremity veins.<sup>45,46</sup> An additional imaging test, however, may affect the NLR and NPV for VTEs on a subsequent chest CT scan. Therefore, if CT is used as the sole imaging test to rule out pulmonary embolism, the actual NLR for a recurrent VTE may be higher and the NPV may be lower than in the present meta-analysis. The

posttest probability of having a VTE following a negative chest CT scan is directly related to the prevalence of pulmonary embolism that varied across the included studies. Thus, the accuracy of chest CT to rule out pulmonary embolism also depends on the presence of risk factors in the population. In contrast to a patient with a low prior probability of a VTE, the posttest probability of having a VTE following a negative chest CT scan may remain substantial in a high-risk patient, and additional imaging tests would be required.

In the absence of an independent standard of reference, we systematically analyzed the clinical validity of a negative CT scan using outcome-based standards.<sup>47</sup> A 3-month follow-up was deemed sufficient because approximately half of all recurrences occur in the first week after a diagnosis of pulmonary embolism has been made.<sup>48</sup> By using follow-up as an outcome measure, NPV may be underestimated if the study population has comorbidities that increase the risk of developing subsequent pulmonary embolism de novo.<sup>22</sup>

Because of the substantial differences between the available diagnostic chest CT modalities, a meta-analysis was deemed necessary to investigate the overall clinical validity of a negative chest CT to rule out clinically significant pulmonary embolism. Variation among studies included direct or indirect follow-up; use of electron-beam CT,<sup>29</sup> single-slice CT,<sup>18,21,23-28,30,31</sup> multidetector-row CT,<sup>22,28</sup> or both single-slice and multidetector-row CT<sup>17</sup>; single<sup>17,19-22,24-26,28-30</sup> or multiple<sup>18,23,27,31</sup> screening methods; overall prevalence of pulmonary embolism (15%-38%); retrospective<sup>19,21,23-26,29</sup> or prospective<sup>17,18,20,22,27,28,30,31</sup> design; academic or community-based settings; and additional imaging tests during enrollment.<sup>18,23,27,31</sup> Although meta-regression and influence analysis did not reveal a significant source of heterogeneity among studies, meta-regression uses summarized data and may provide an inaccurate impression of patient characteristics.

Although guidelines exist for meta-analyses in evaluating diagnostic tests,<sup>49,50</sup> there is no agreed method to assess publication bias for diagnostic meta-analysis.<sup>51</sup> We recognize that we undoubtedly overlooked foreign-language studies and unpublished data. Also, differential reference standard bias<sup>52</sup> may be present among patients with negative findings, who may represent a healthier population than those with positive findings. The patients from the included studies are not necessarily representative of the entire population of patients with suspected pulmonary embolism because contrast-enhanced chest CT was not performed in patients with severe renal dysfunction, or in patients with a history of anaphylactic reaction to iodine contrast, or in patients who were pregnant.

Overall, our results suggest that withholding anticoagulant therapy after a negative CT scan appears to be safe. Additional imaging for ruling out pulmonary embolism is not warranted. This strategy may minimize radiation exposure, invasive procedures, and health care costs.

**Author Contributions:** Dr Schoepf had full access to all of the data in the study and takes responsibility for the integrity of the data and the accuracy of the data analysis.

**Study concept and design:** Zou, Costello, Goldhaber, Kucher, Schoepf.

**Acquisition of data:** Quiroz, Kipfmüller, Schoepf.  
**Analysis and interpretation of data:** Quiroz, Zou, Goldhaber, Kucher, Schoepf.

**Drafting of the manuscript:** Quiroz, Zou, Schoepf.  
**Critical revision of the manuscript for important intellectual content:** Zou, Kipfmüller, Costello, Goldhaber, Kucher, Schoepf.

**Statistical analysis:** Quiroz, Zou, Kucher.

**Administrative, technical, or material support:** Kipfmüller, Goldhaber.

**Study supervision:** Costello, Goldhaber, Kucher, Schoepf.

**Financial Disclosures:** Dr Zou has received funding from the National Institutes of Health. None of the other authors reported financial disclosures.

## REFERENCE

- Schoepf UJ, Goldhaber SZ, Costello P. Spiral computed tomography for acute pulmonary embolism. *Circulation*. 2004;109:2160-2167.
- Stein PD, Kayali F, Olson RE. Trends in the use of diagnostic imaging in patients hospitalized with acute pulmonary embolism. *Am J Cardiol*. 2004;93:1316-1317.
- Goodman LR, Curtin JJ, Mewissen MW, et al. Detection of pulmonary embolism in patients with unresolved clinical and scintigraphic diagnosis: helical CT

- versus angiography. *AJR Am J Roentgenol.* 1995;164:1369-1374.
4. Drucker EA, Rivitz SM, Shepard JA, et al. Acute pulmonary embolism: assessment of helical CT for diagnosis. *Radiology.* 1998;209:235-241.
  5. Perrier A, Howarth N, Didier D, et al. Performance of helical computed tomography in unselected outpatients with suspected pulmonary embolism. *Ann Intern Med.* 2001;135:88-97.
  6. Zuckerman DA, Sterling KM, Oser RF. Safety of pulmonary angiography in the 1990s. *J Vasc Interv Radiol.* 1996;7:199-205.
  7. Stein PD, Hull RD. Relative risks of anticoagulant treatment of acute pulmonary embolism based on an angiographic diagnosis vs a ventilation/perfusion scan diagnosis. *Chest.* 1994;106:727-730.
  8. Stein PD, Henry JW, Gottschalk A. Reassessment of pulmonary angiography for the diagnosis of pulmonary embolism: relation of interpreter agreement to the order of the involved pulmonary arterial branch. *Radiology.* 1999;210:689-691.
  9. Diffin DC, Leyendecker JR, Johnson SP, Zucker RJ, Grebe PJ. Effect of anatomic distribution of pulmonary emboli on interobserver agreement in the interpretation of pulmonary angiography. *AJR Am J Roentgenol.* 1998;171:1085-1089.
  10. Lorut C, Ghossains M, Horellou MH, Achkar A, Fretault J, Laaban JP. A noninvasive diagnostic strategy including spiral computed tomography in patients with suspected pulmonary embolism. *Am J Respir Crit Care Med.* 2000;162:1413-1418.
  11. Bourriot K, Couffignal T, Bernard V, Montaudon M, Bonnet J, Laurent F. Clinical outcome after a negative spiral CT pulmonary angiographic finding in an inpatient population from cardiology and pneumology wards. *Chest.* 2003;123:359-365.
  12. Musset D, Parent F, Meyer G, et al. Diagnostic strategy for patients with suspected pulmonary embolism: a prospective multicentre outcome study. *Lancet.* 2002;360:1914-1920.
  13. Garg K, Welsh CH, Feyerabend AJ, et al. Pulmonary embolism: diagnosis with spiral CT and ventilation-perfusion scanning—correlation with pulmonary angiographic results or clinical outcome. *Radiology.* 1998;208:201-208.
  14. Blachere H, Latrabe V, Montaudon M, et al. Pulmonary embolism revealed on helical CT angiography: comparison with ventilation-perfusion radionuclide lung scanning. *AJR Am J Roentgenol.* 2000;174:1041-1047.
  15. Irwin GA, Luchs JS, Donovan V, Katz DS. Can a state-of-the-art D-dimer test be used to determine the need for CT imaging in patients suspected of having pulmonary embolism? *Acad Radiol.* 2002;9:1013-1017.
  16. van Strijen MJ, de Monye W, Kieft GJ, et al. Diagnosis of pulmonary embolism with spiral CT as a second procedure following scintigraphy. *Eur Radiol.* 2003;13:1501-1507.
  17. Donato AA, Scheirer JJ, Atwell MS, Gramp J, Duszak R Jr. Clinical outcomes in patients with suspected acute pulmonary embolism and negative helical computed tomographic results in whom anticoagulation was withheld. *Arch Intern Med.* 2003;163:2033-2038.
  18. Ferretti GR, Bosson JL, Buffaz PD, et al. Acute pulmonary embolism: role of helical CT in 164 patients with intermediate probability at ventilation-perfusion scintigraphy and normal results at duplex US of the legs. *Radiology.* 1997;205:453-458.
  19. Garg K, Sieler H, Welsh CH, Johnston RJ, Russ PD. Clinical validity of helical CT being interpreted as negative for pulmonary embolism: implications for patient treatment. *AJR Am J Roentgenol.* 1999;172:1627-1631.
  20. Goodman LR, Lipchik RJ, Kuzo RS, Liu Y, McAuliffe TL, O'Brien DJ. Subsequent pulmonary embolism: risk after a negative helical CT pulmonary angiogram—prospective comparison with scintigraphy. *Radiology.* 2000;215:535-542.
  21. Gottsäter A, Berg A, Centergard J, Frennby B, Nirhov N, Nyman U. Clinically suspected pulmonary embolism: is it safe to withhold anticoagulation after a negative spiral CT? *Eur Radiol.* 2001;11:65-72.
  22. Kavanagh EC, O'Hare A, Hargaden G, Murray JG. Risk of pulmonary embolism after negative MDCT pulmonary angiography findings. *AJR Am J Roentgenol.* 2004;182:499-504.
  23. Krestan CR, Klein N, Fleischmann D, et al. Value of negative spiral CT angiography in patients with suspected acute PE: analysis of PE occurrence and outcome. *Eur Radiol.* 2004;14:93-98.
  24. Lombard J, Bhatia R, Sala E. Spiral computed tomographic pulmonary angiography for investigating suspected pulmonary embolism: clinical outcomes. *Can Assoc Radiol J.* 2003;54:147-151.
  25. Lomis NN, Yoon HC, Moran AG, Miller FJ. Clinical outcomes of patients after a negative spiral CT pulmonary arteriogram in the evaluation of acute pulmonary embolism. *J Vasc Interv Radiol.* 1999;10:707-712.
  26. Nilsson T, Olausson A, Johnsson H, Nyman U, Aspelin P. Negative spiral CT in acute pulmonary embolism. *Acta Radiol.* 2002;43:486-491.
  27. Ost D, Rozenshtein A, Saffran L, Snider A. The negative predictive value of spiral computed tomography for the diagnosis of pulmonary embolism in patients with nondiagnostic ventilation-perfusion scans. *Am J Med.* 2001;110:16-21.
  28. Remy-Jardin M, Tillie-Leblond I, Szapiro D, et al. CT angiography of pulmonary embolism in patients with underlying respiratory disease: impact of multisllice CT on image quality and negative predictive value. *Eur Radiol.* 2002;12:1971-1978.
  29. Swensen SJ, Sheedy PF II, Ryu JH, et al. Outcomes after withholding anticoagulation from patients with suspected acute pulmonary embolism and negative computed tomographic findings: a cohort study. *Mayo Clin Proc.* 2002;77:130-138.
  30. Tillie-Leblond I, Mastora I, Radenne F, et al. Risk of pulmonary embolism after a negative spiral CT angiogram in patients with pulmonary disease: 1-year clinical follow-up study. *Radiology.* 2002;223:461-467.
  31. van Strijen MJ, de Monye W, Schiereck J, et al. Single-detector helical computed tomography as the primary diagnostic test in suspected pulmonary embolism: a multicenter clinical management study of 510 patients. *Ann Intern Med.* 2003;138:307-314.
  32. Egger M, Davey Smith G, Schneider M, Minder C. Bias in meta-analysis detected by a simple, graphical test. *BMJ.* 1997;315:629-634.
  33. Begg CB, Berlin JA. Publication bias and dissemination of clinical research. *J Natl Cancer Inst.* 1989;81:107-115.
  34. Normand SL. Meta-analysis: formulating, evaluating, combining, and reporting. *Stat Med.* 1999;18:321-359.
  35. Thompson SG. Why and how sources of heterogeneity should be investigated. In: Egger M, Davey Smith G, Altman DG, eds. *Systematic Reviews in Health Care: Meta-analysis in Context.* London, England: BMJ Publishing Group; 2001:157-174.
  36. Thompson SG, Pocock SJ. Can meta-analyses be trusted? *Lancet.* 1991;338:1127-1130.
  37. Deeks JJ, Altman DG, Bradburn MJ. Statistical methods for examining heterogeneity and combining results from several studies in meta-analysis. In: Egger M, Davey Smith G, Altman DG, eds. *Systematic Reviews in Health Care: Meta-analysis in Context.* London, England: BMJ Publishing Group; 2001.
  38. Tobias A. Sbe26: assessing the influence of a single study in meta-analysis. *STATA Tech Bull.* 1999;47:15-17.
  39. van Beek EJ, Reekers JA, Batchelor DA, Brandjes DP, Buller HR. Feasibility, safety and clinical utility of angiography in patients with suspected pulmonary embolism. *Eur Radiol.* 1996;6:415-419.
  40. Henry JW, Relyea B, Stein PD. Continuing risk of thromboemboli among patients with normal pulmonary angiograms. *Chest.* 1995;107:1375-1378.
  41. PIOPE Investigators. Value of the ventilation/perfusion scan in acute pulmonary embolism: results of the Prospective Investigation of Pulmonary Embolism Diagnosis (PIOPE). *JAMA.* 1990;263:2753-2759.
  42. Ghaye B, Szapiro D, Mastora I, et al. Peripheral pulmonary arteries: how far in the lung does multi-detector row spiral CT allow analysis? *Radiology.* 2001;219:629-636.
  43. Patel S, Kazerooni EA, Cascade PN. Pulmonary embolism: optimization of small pulmonary artery visualization at multi-detector row CT. *Radiology.* 2003;227:455-460.
  44. Schoepf UJ, Holzknecht N, Helmlinger TK, et al. Subsegmental pulmonary emboli: improved detection with thin-collimation multi-detector row spiral CT. *Radiology.* 2002;222:483-490.
  45. Cham MD, Yankelevitz DF, Shaham D, et al. Pulmonary Angiography-Indirect CT Venography Cooperative Group. Deep venous thrombosis: detection by using indirect CT venography. *Radiology.* 2000;216:744-751.
  46. Loud PA, Katz DS, Bruce DA, Klippenstein DL, Grossman ZD. Deep venous thrombosis with suspected pulmonary embolism: detection with combined CT venography and pulmonary angiography. *Radiology.* 2001;219:498-502.
  47. Wolfe TR, Hartsell SC. Pulmonary embolism: making sense of the diagnostic evaluation. *Ann Emerg Med.* 2001;37:504-514.
  48. Carson JL, Kelley MA, Duff A, et al. The clinical course of pulmonary embolism. *N Engl J Med.* 1992;326:1240-1245.
  49. Deeks JJ. Systematic reviews of evaluations of diagnostic and screening tests. In: Egger M, Davey Smith G, Altman DG, eds. *Systematic Reviews in Health Care: Meta-analysis in Context.* London, England: BMJ Publishing Group; 2001:248-282.
  50. Irwig L, Tosteson AN, Gatsonis C, et al. Guidelines for meta-analyses evaluating diagnostic tests. *Ann Intern Med.* 1994;120:667-676.
  51. Irwig L, Macaskill P, Glasziou P, Fahey M. Meta-analytic methods for diagnostic test accuracy. *J Clin Epidemiol.* 1995;48:119-132.
  52. Lijmer JG, Mol BW, Heisterkamp S, et al. Empirical evidence of design-related bias in studies of diagnostic tests. *JAMA.* 1999;282:1061-1066.